

**Case Report**

Case Reports on Juvenile Xanthogranuloma and Brief Review of Literature

Sushmita Pradhan¹, Shuang Chen², Lin Xiong^{1,*}¹Department of Dermatovenereology, West China Hospital, Sichuan University, Chengdu, China²Department of Dermatology, The First Affiliated Hospital of Chongqing Medical University, Chongqing, China**Email address:**

sush_pradhan@hotmail.com (S. Pradhan), 179409599@qq.com (Shuang Chen), xionglin2k@163.com (Lin Xiong)

*Corresponding author

To cite this article:Sushmita Pradhan, Shuang Chen, Lin Xiong. Case Reports on Juvenile Xanthogranuloma and Brief Review of Literature. *Science Journal of Clinical Medicine*. Vol. 6, No. 5, 2017, pp. 82-85. doi: 10.11648/j.sjcm.20170605.14**Received:** February 18, 2017; **Accepted:** March 18, 2017; **Published:** October 24, 2017

Abstract: Juvenile xanthogranuloma is an unusual, self-limiting dermatological disorder occurring especially in infants, late childhood and rarely in adults. It belongs to the broad group of non-Langerhans cell histiocytosis. It usually appears as solitary or multiple papules, macules or nodules several millimeters in diameter with the head and neck being the most common site of involvement and vulva being the rare site. We report two cases of juvenile xanthogranuloma in an 18 months old female and 18 months old male. The female presented with three yellow papules measuring 2-3 mm in diameter around vulva region since 4 months. Similarly, the male presented with multiple tan-orange color macules on head and forehead measuring 3-4mm in diameter since 6 months. In both the cases, a biopsy without total excision was performed. The clinical and histopathological evaluation confirmed the diagnosis of juvenile xanthogranuloma. In childhood, juvenile xanthogranuloma is necessary to differentiate from another probable differential diagnosis by biopsy.

Keywords: Xanthogranuloma, Juvenile, Children

1. Introduction

Juvenile xanthogranuloma (JXG) is an unusual disorder belonging to the group of non-Langerhans cell histiocytosis [1]. In the first two decades of life, most cases of xanthogranulomas present as multiple, self-limited, cutaneous lesions in children, and hence has been defined as juvenile xanthogranuloma [2, 3]. It is clinically characterized by asymptomatic single or multiple papules, macules or nodules usually tan-orange color ranging from several millimeters in diameter which does not require treatment [4]. Although the presence of lesions on the trunk, extremities, and extracutaneous locations has been reported, the common sites include the head and neck [4, 5]. The extracutaneous sites involving the eye, lung, abdominal viscera and skull has been reported in the literature. Histologically, JXG is composed of collections of histiocytes, foamy cells and Touton giant cells (seen in 85% of JXG, in recent studies) [1]. The diagnosis of JXG is mainly based on clinical evaluation

and sometimes biopsy [6]. The skin lesions usually resolve spontaneously. This article presented a female and a male diagnosed as juvenile xanthogranuloma confirmed by biopsy.

2. Case Report

Case A

Case A was an 18-month-old female who presented to our center with papules in the vulva. She was born at 39 weeks' gestational age, without any abnormality or history of trauma at birth. The lesion was first noted at 14 months of age. The papule was three in number with 2-3 millimeters in diameter, yellow in color. [Figure 1(a)] A biopsy without total excision was performed from the lesion at the vulva. The histological evaluation revealed foamy histiocytes and numerous Touton giant cells with eosinophils. [Figure 1(b)] Immunohistochemistry examination was not performed. Hence, the clinical evaluation and biopsy confirmed the diagnosis of Juvenile xanthogranuloma in the vulva. No, any

treatment was given, as the lesions resolved spontaneously after few months of follow-up.

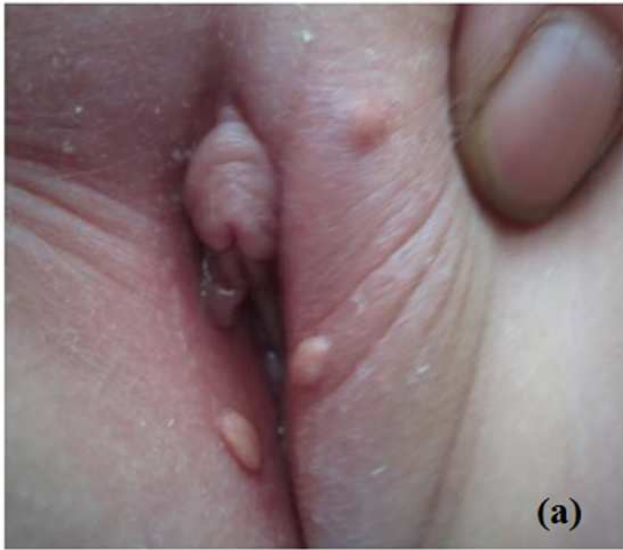

Figure 1a. An 18-month old female child developed papules with 2-3 millimeters in diameter in the vulva.

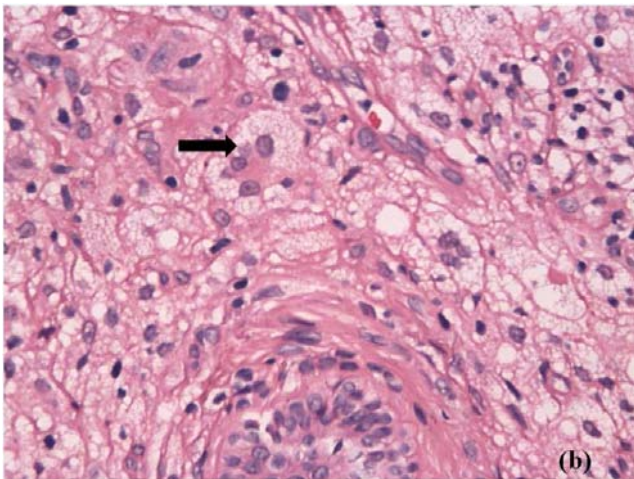


Figure 1b. Haematoxylin-eosin staining of the yellowish papule in the vulva at 18 months of age. Numerous foam cells are seen throughout the dermis. Arrows indicate Touton giant cells. (original magnification X 400).

Case B

Case B was an 18-month-old male who presented to our center with macules on head and forehead. He was born at 40 weeks' gestational age, without any abnormality or history of trauma at birth. The lesion was first noted at 12 months of age. The macules were multiple in number with 3-4 millimeters in diameter, tan-orange in color. [Figure 2(a)] Similarly, in order to confirm the diagnosis a biopsy without total excision was performed from the macules. The histological evaluation revealed foamy histiocytes and numerous Touton giant cells with eosinophils. [Figure 2(b)] Immunohistochemistry examination was not performed. The diagnosis of Juvenile xanthogranuloma on the head and forehead was made clinically with the help of biopsy. Also, this case received no treatment and the lesions resolved

spontaneously after few months of follow-up.

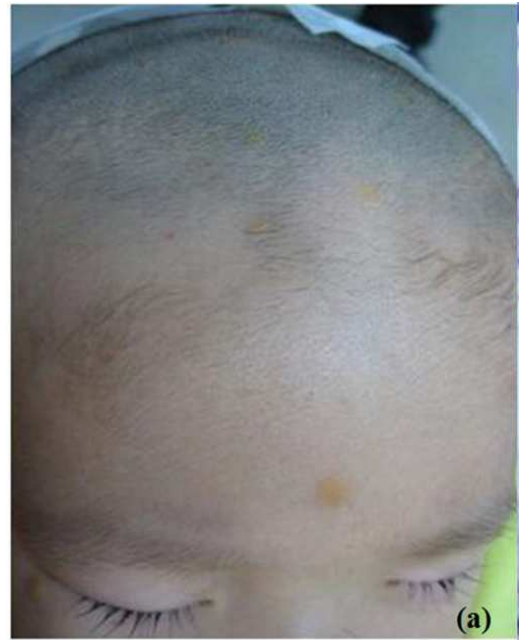

Figure 2a. An 18-month old male child presented with tan-orange macules 3-4 millimeter in diameter on head and forehead.

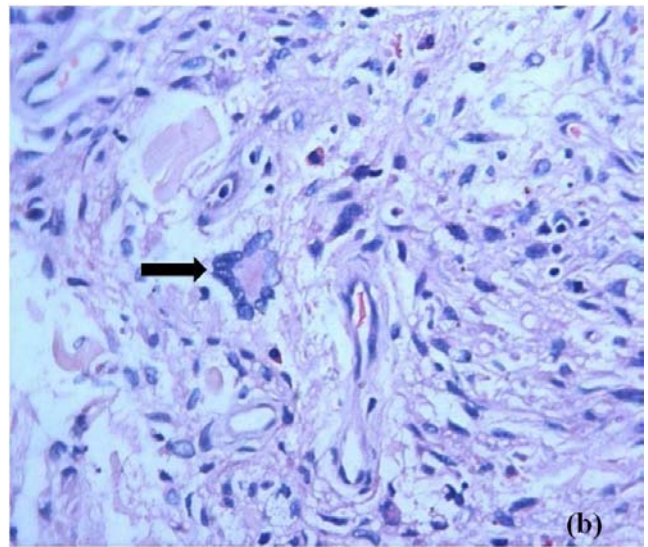


Figure 2b. Haematoxylin-eosin staining of the tan-orange macule on the head at 18 months of age. Many foam cells are seen in the dermis. Arrow indicate Touton giant cells and foam cells. (original magnification X 400).

3. Discussion

Juvenile xanthogranulomas or the histiocytic disorders were first described by H. G. Adamson nearly 112 years ago [7]. It is one of the dendritic cell-related disorders, classified as a non-Langerhans cell histiocytosis (LCH) disease together with several other histiocytic entities including papular xanthoma, benign cephalic histiocytosis, sinus histiocytosis with massive lymphadenopathy (Rosai-Dorfman disease), and hemophagocytic histiocytosis [8]. Although the main cause of JXG is still unknown Kitchen *et. al* believed to

as result from a disordered macrophage response to a non-specific injury [9].

The location of cutaneous lesions in case A in vulva is rarely reported in the literature in children however the location of case B on the head and forehead, is the commonest location of JXG. Minority of 5-10% patients have been reported to have extracutaneous involvement with its commonest sites involving the uveal tract, oropharynx, heart, lung, liver and other organs [10]. The appearance of cutaneous lesions mainly affects infants and small children, 64% of cutaneous lesions by age 7 months and 85% before 1 year has been reported so far [11]. In both of our case, the patients' age was around 1 year which is the commonest age for the occurrence of cutaneous lesions. Winkelmann reported no any sexual or racial predilection of JXG [12]. However, the male to female ratio of 1.5:1 cutaneous JXG in children has been reported in the literature. Three cases of JXG comprising one male and two female children with cutaneous lesions on head and neck has been reported in Chinese literature [13]. Rarely the cases of JXG in vulva has been reported in Chinese literature. In 1997 Campourcy M et al., reported cutaneous nodule in an 18-month old child in labia majora and chin, diagnosed as langerhans cell histiocytosis due to lack of giant cells [14]. The first case of JXG nodule in the vulva was reported in a 10-year-old girl by Gupta et. al [15]. Polat et. al reported Spitz nevus being the rare differential diagnosis of JXG in vulva in an 11-year-old girl [16]. Rodriguez and Ackerman described xanthogranulomas at multiple locations with lesions on the face, scalp, axilla and genitalia however other sites of origin were not specified in their published article [17]. However, irrespective of sites of the asymptomatic lesion in children may lead to the matter of concern in parents. Therefore, children with JXG can be evaluated and possible malignancy can be ruled out by the clinicians. Only handful of cases involving xanthogranulomas in vulva in adult age group is reported in the literature [18, 19, 20].

Most of the time when not confirmed histologically, JXG is diagnosed clinically that may lead to misdiagnosis by the clinicians. The first differential diagnosis of JXG is Langerhans Cell Histiocytosis [21]. The other differential diagnosis of JXG includes spitz nevi, mastocytomas and dermatofibromas [1]. Reticulohistocytoma [15], malignant fibrous histiocytoma [22] and embryonal rhabdysarcoma [23] also must be kept as the differential diagnosis for vulval nodules. Reticulohistocytoma is a non-Langerhan cell histiocytosis group of histiocytic disorder characterized by large mononucleated or multinucleated histiocytes. Malignant fibrous histiocytoma mainly occurs in elderly age group characterized by pleomorphism, mitosis, necrosis and tumor giant cells. Whereas embryonal rhabdysarcoma is common in pediatric age group with JXG. The cases of JXG presenting in vulva is extremely rare in literature both in children and adult.

Janssen and colleagues classified histologic patterns of JXG into three categories namely early JXG, classic JXG and transitional JXG [21]. Early JXG exhibits sheets of small to intermediate-sized mono nuclear histiocytes, absence of

Touton-type giant cells and lack of atypia in cells with more mitosis. Classic JXG shows an appearance of JXG with the presence of abundant vacuolated, foamy histiocytes and Touton giant cells. And transitional JXG shows spindle-shaped cells resembling Benign Fibrous Histiocytoma with foamy histiocytes and occasional giant cells [21]. Overall, histologic findings in JXG are dense dermal histiocytic infiltrate and Touton Giant cells which are multinucleated, with homogeneous eosinophilic cytoplasmic center and xanthomatization in the periphery [6]. The histological examination is necessary and both our cases matched with the classic JXG classification of JXG with the presence of foamy histiocytes and numerous Touton giant cells with eosinophils. The diagnosis of JXG is mainly based on its clinical features and skin biopsy for its confirmation.

Immunohistochemistry plays an important role in the diagnosis between JXG and Langerhans cell histiocytosis. But immunohistochemistry for CD1a, S-100, and langerin can only be performed in cases of suspicion [24]. The immunohistochemistry examination was not performed in both of our cases. The cutaneous JXG usually improves spontaneously without any treatment or surgical excision of nodule when required and also the clinicians can wait and watch to see any progression or regression of the lesions. The lesions may resolve completely or leave a residual atrophic or hyperpigmented scar. The lesions in both the cases resolved spontaneously after few months of its follow-up. The recurrence of JXG is uncommon and has been documented [25].

Therefore, we report two cases of cutaneous lesions of JXG one in an uncommon site in the vulva region while the other case in the head and forehead. JXG is one of the non-langerhans histiocytic proliferation frequently seen in infants and children. Excision of the lesion is usually performed for confirmed diagnosis and aesthetic reasons. Only handful of cases of JXG in the vulva has been reported. So one of the cases from this article might be helpful for reference in future. In order to avoid misdiagnosis of JXG, clinicians should be well aware where a detailed history and examination is necessary to rule out any possible malignancies.

4. Conclusion

All in all, although vulval JXG has been reported in adults, it is rarely reported in pediatric age group. The cutaneous lesions of JXG are self-regressive and have a better prognosis in children. Hence, clinicians should always keep in mind spitz nevi, mastocytomas and dermatofibromas in the differential diagnosis of JXG. In suspected cases of JXG, histopathological examination should be done.

Abbreviations

JXG: Juvenile xanthogranuloma

LCH: Langerhans cell histiocytosis

References

- [1] Dehner LP. Juvenile xanthogranuloma in the first decades of life. A clinicopathologic study of 174 cases with cutaneous and extracutaneous manifestations. *Am J Surg Pathol.* 2003; 5: 579-593.
- [2] George DH, Scheithauer BW, Hilton DL, Fakhouri AJ, Kraus EW. Juvenile xanthogranuloma of peripheral nerve: a report of two cases. *Am J Surg Pathol.* 2001; 25: 521-526.
- [3] Lesniak MS, Viglione MP, Weingart J. Multicentric parenchymal xanthogranuloma in a child: case report and review of the literature. *Neurosurgery.* 2002; 51: 1493-1498.
- [4] Hernandez-Martin A, Baselga E, Drolet BA, Esterly NB. Juvenile xanthogranuloma. *J Am Acad Dermatol.* 1997; 36: 335-367.
- [5] Cypel TKS, Zuker RM. Juvenile xanthogranuloma: case report and review of the literature. *Can J Plast Surg.* 2008; 16: 175-177.
- [6] Sanguenza OP, Salmon JK, White CR Jr, Beckstead JH. Juvenile xanthogranuloma: a clinical histopathologic and immunohistochemical study. *J Cutan Pathol.* 1995; 22: 327-335.
- [7] Adamson HG. Society intelligence: The dermatologic society of London. *Br J Dermatol.* 1905; 17: 222.
- [8] Burgdorf WHC, Zelger B. Then on Langerhan's cell histiocytosis in childhood. *Cutis.* 1996; 58: 201-207.
- [9] Kitchen ND, Davies MS, Taylor W. Juvenile xanthogranuloma of nerve root origin. *Br J Neurosurg.* 1995; 9: 233-237.
- [10] Janssen D, Harms D. Juvenile xanthogranuloma in childhood and adolescence: A clinicopathologic study of 129 patients from the kiel pediatric tumor registry. *Am J Surg Pathol.* 2005; 29: 21-28.
- [11] Curtis T, Wheeler DT, Cibis GW, Law SK, Rowsey JJ, Brown LL, Roy H. Juvenile xanthogranuloma: [http://emedicine.medscape.com/article/1209681-overview]
- [12] Winkelmann RK. Cutaneous syndrome of non-X histiocytosis: A review of the macrophage histiocytosis of the skin. *Arch Dermatol.* 1981; 117: 667-72.
- [13] Liu ZQ, Liu R, Shi XD, Li JX, Zou JZ. Juvenile xanthogranuloma: 3 cases report and literature review. *Zhonghua XueYe Xue Za Zhi.* 2011. Sep; 32 (9): 614-7.
- [14] Campoury M, Moreau-Cabarrot A, Gorguet B, Samalens G, Daste B, Eclache F, et al. Acquired regressive cutaneous non-Langerhans'-cell histiocytosis in an infant. *Ann Dermatol Venereol.* 1997; 124: 167-70.
- [15] Gupta B, Yadav S, Khurana N, Sharma M. Juvenile xanthogranuloma in vulva of a 10-year-old child. *Journal of Clinical and Diagnostic Research.* 2016; 11: ED21-ED22.
- [16] Polat M, Topcuoglu MA, Tahtaci Y, Hapa A, Yilmaz F. Spitz nevus of the genital mucosa. *Indian J Dermatol Venereol Leprol.* 2009; 75: 167-69.
- [17] Rodriguez J, Ackerman B. Xanthogranuloma in adults. *Arch Dermatol.* 1976; 112: 43-44.
- [18] Castillo EA, Orms by-Adult xanthogranuloma of the vulva: case report and review. *Pathology.* 2002; 34: 86-87.
- [19] DeLuca IJ, Grossman ME. Vulvar necrobiotic xanthogranuloma. *Journal of the American Academy of Dermatology.* 2014; 71: e247-48.
- [20] Tran DT, Wolgamot GM, Olerud J, Hurst S, Argenyi Z. An 'eruptive' variant of juvenile xanthogranuloma associated with langerhans cell histiocytosis. *Journal of Cutaneous Pathology.* 2008; 35: 50-55.
- [21] Janssen D, Harms D. Juvenile xanthogranuloma in childhood and adolescence: a clinicopathologic study of 129 patients from the kiel pediatric tumor registry. *Am J Surg Pathol.* 2005; 29: 21-28.
- [22] Santala M, Suonio S, Syrjanen K, Uronen MT, Saarikoski S. Malignant fibrous histiocytoma of the vulva. *Gynecologic Oncology.* 1987; 27: 121-26.
- [23] Youngstrom EA, Bartkowski DP. Vulvar embryonal rhabdomyosarcoma: A case report. *Journal of Pediatric Urology.* 2013; 9 (4): e144-46.
- [24] Park HJ, Jeon YK, Lee AH, Oh YH, Park SH, Jung KC. Use of the JLEpitope, which encompasses the non glycosylation site of CD43, as a marker of immature/neoplastic Langerhans cells. *Am J Surg Pathol.* 2012; 36: 1150-57.
- [25] Cohen BA, Hood A. Xanthogranuloma: Report on clinical and histologic findings in 64 patients. *Pediatr Dermatol.* 1989; 6: 262-6.